



2025 Winter CE Conference

February 1 and 2

Dr. Amelie McAndrews
DVM, DAVDC-Eq bio
Clinical Associate, UPenn
Garden State Equine Dentistry

Case Studies

Generously sponsored by:



AmerisourceBergen
MWI Animal Health®



Equine dental case studies: When things go as planned (and when they don't)

Amelie McAndrews, DVM, DAVDC-Eq
Principal, Garden State Equine Vet. Dentistry
Clinical Associate, University of Pennsylvania's New Bolton Center



1

Common problems

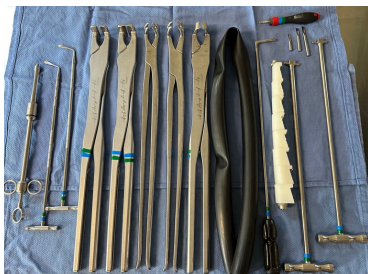
- Unsuccessful routine oral tooth extraction
- Pulp horn defect, caries, or fracture?
- Unsuccessful periodontal disease management
- Persistent sinusitis



2

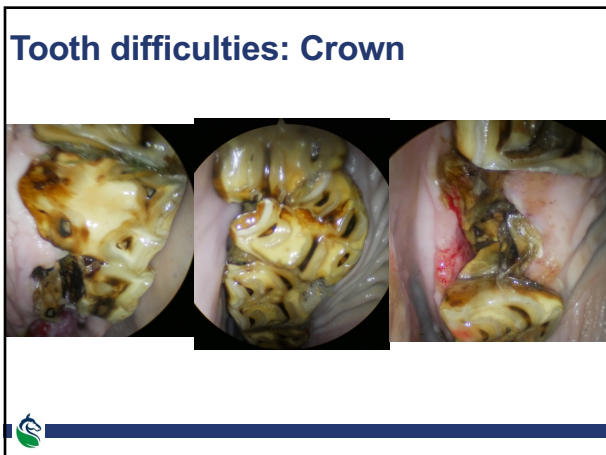Clinician difficulties

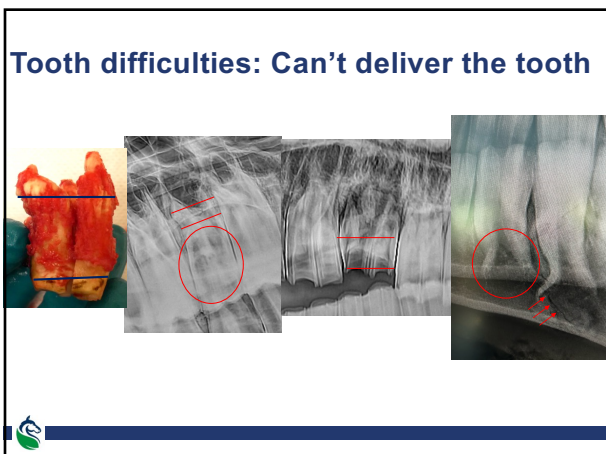
- Do you have the time, desire, skills and instruments to complete the extraction?



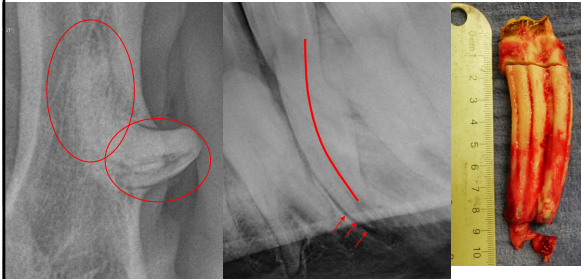
3





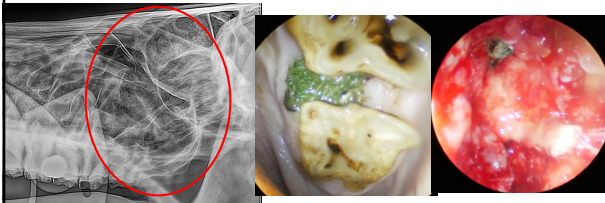


Tooth difficulties: Can't deliver the tooth



7

Problems related to the tooth



8

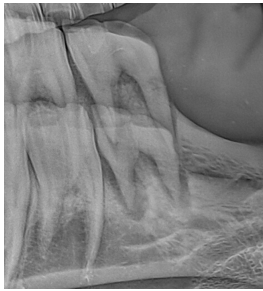Final Tips

- Schedule more time than you think you'll need
- If you aren't making process in 15 minute intervals, stop and reassess
- Set realistic expectations, even when you are confident you'll be able to successfully extract the tooth
- Have plan ABCD...
- Bring snacks



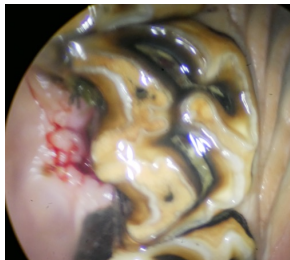
9

Routine oral extraction?



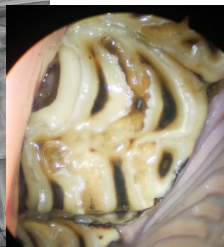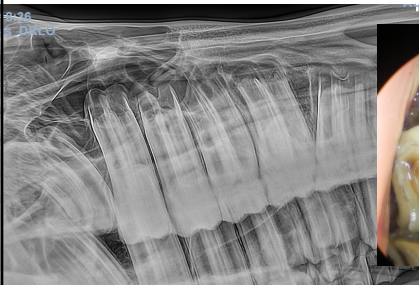10

Routine oral extraction?



11

Routine oral extraction?

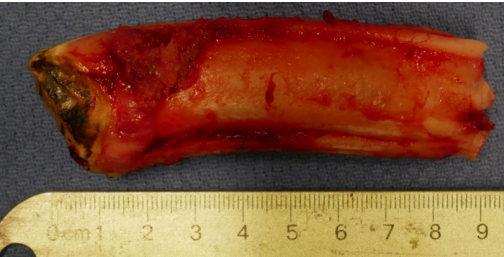

3 yo SB colt



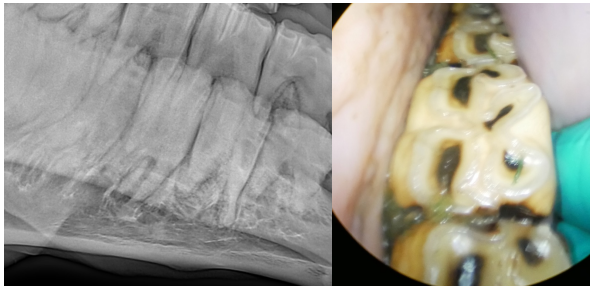
12

Routine oral extraction?



13

Routine oral extraction?

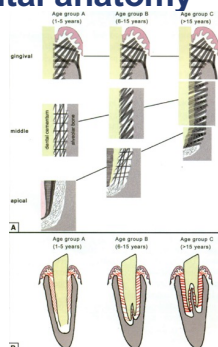


20 yo TB G



14

Periodontal anatomy

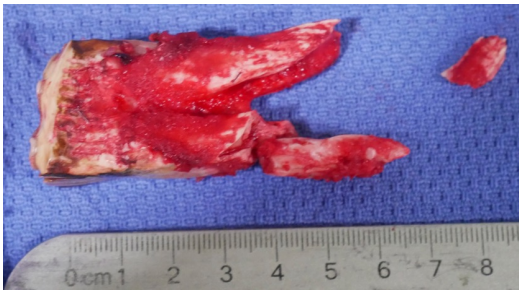

Staszuk C et al. Collagen Fiber Architecture of the periodontal ligament in equine cheek teeth. JVD. 23:3. Sept 2006



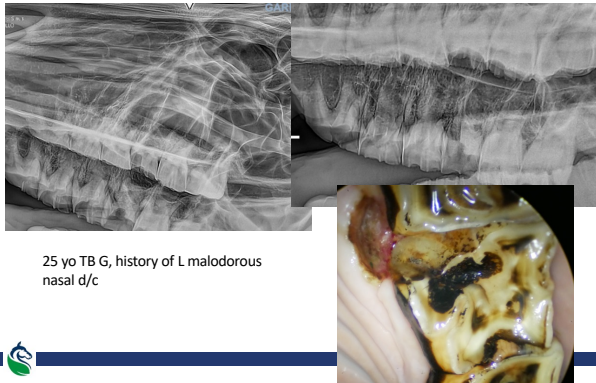
15

Routine oral extraction?



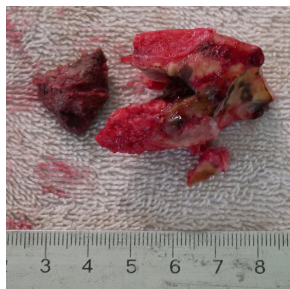
16

Routine oral extraction?



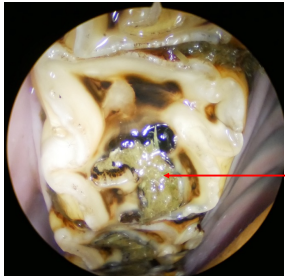
17

Routine oral extraction?

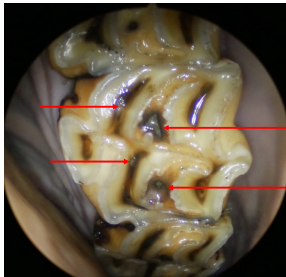


18

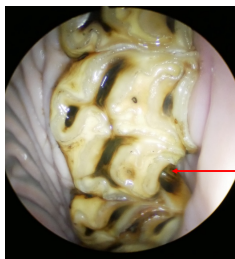
Pulp horn defect, caries, or fracture?



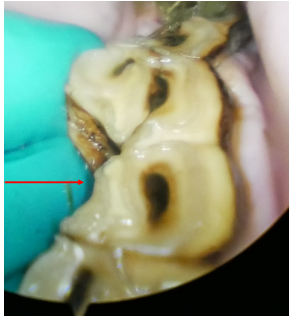19



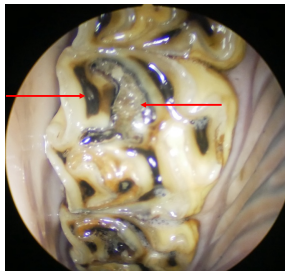
20



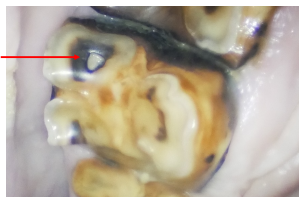
21



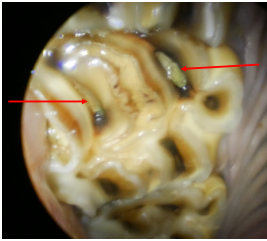
22



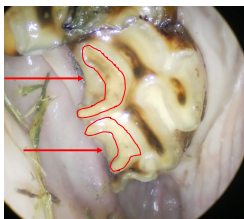
23



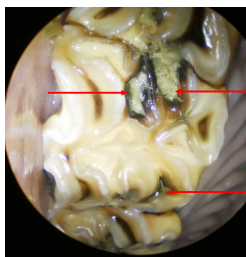
24



25



26



27

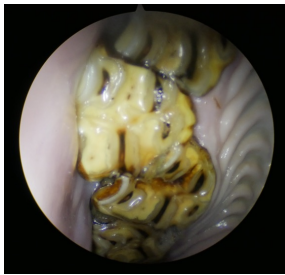
Periodontal disease

- Senile diastema and diastema due to bucco- or mesio- version can be very frustrating
- Extraction sometime is more cost effective and more successful

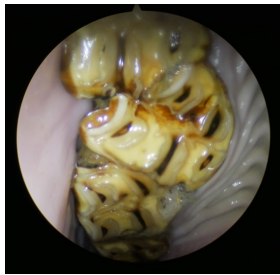


28

Periodontal disease



106, 107, 108



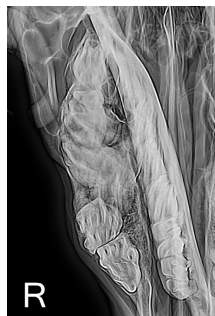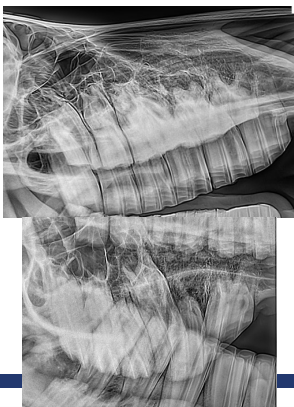
107, 108, 109

Dolly 14 yo mini mare 1/19/19

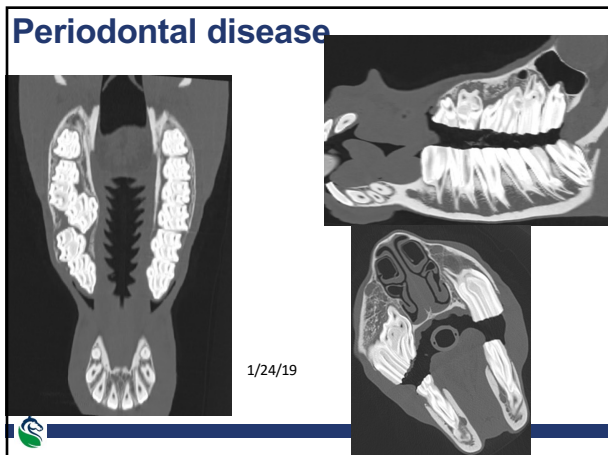


29

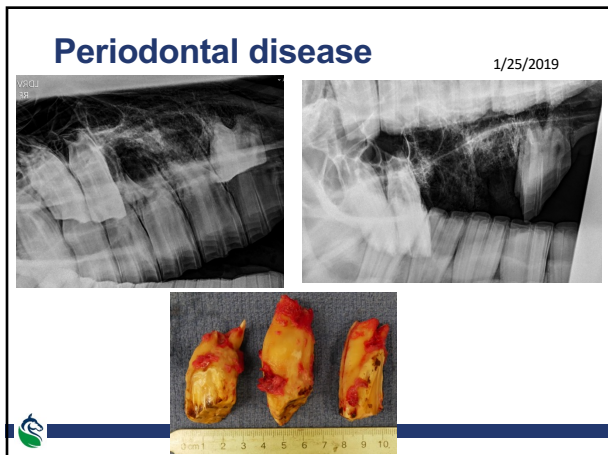
Periodontal disease



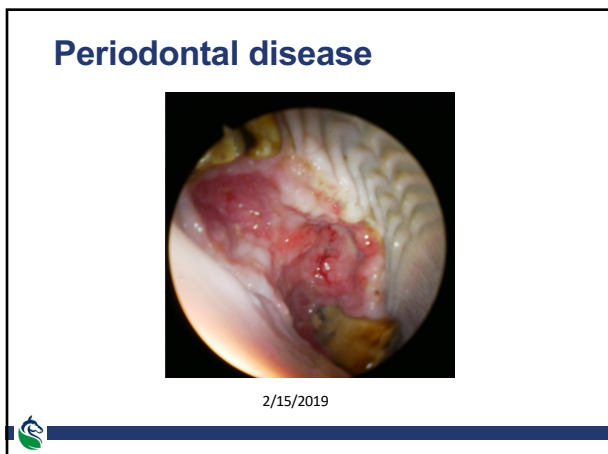30



31

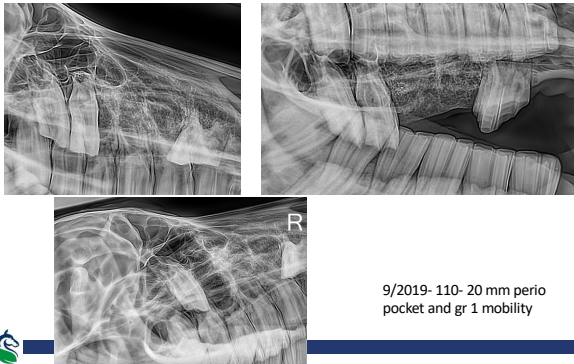


32



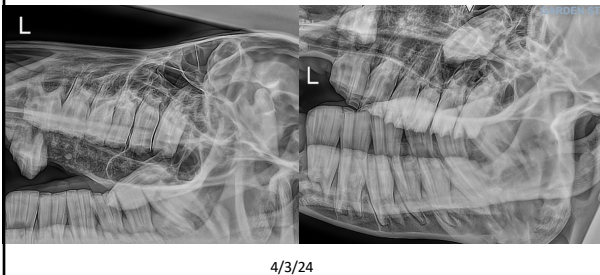33

Periodontal disease



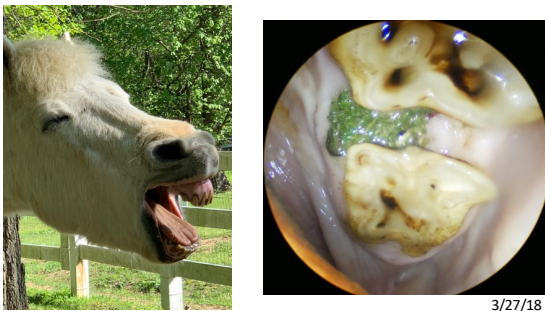
34

Periodontal disease



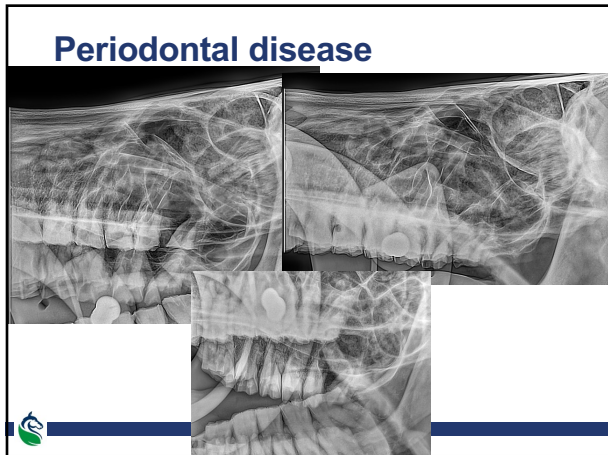
35

Periodontal disease

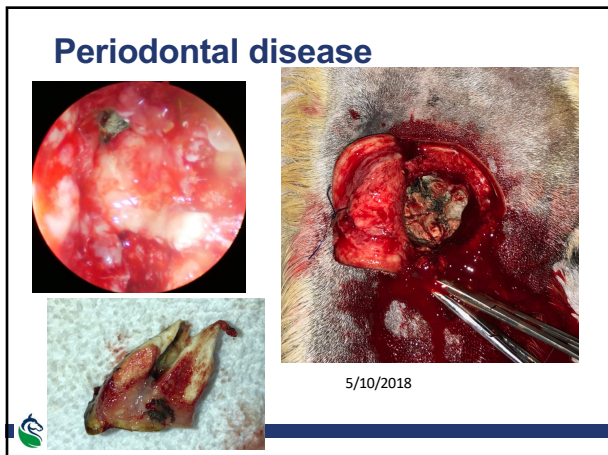

Aged pony G with PPID

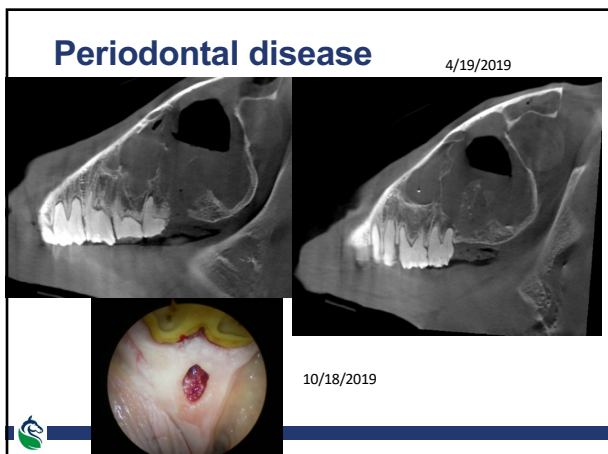
36



37



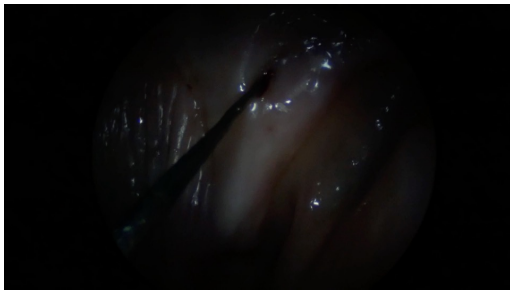
38



39

Periodontal disease

12/12/2019



40

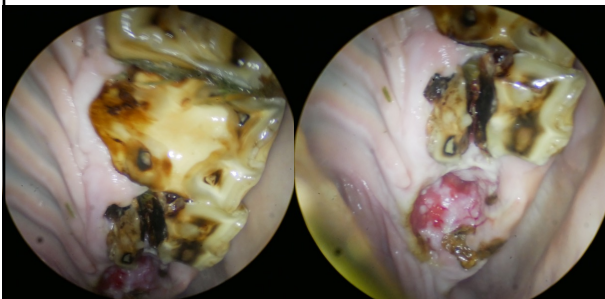
Persistent sinusitis

- 27 yo WB G
- 9 mo history of malodorous L nasal discharge
- Treated with several rounds of antimicrobials
- Lay floater tried to extract 211



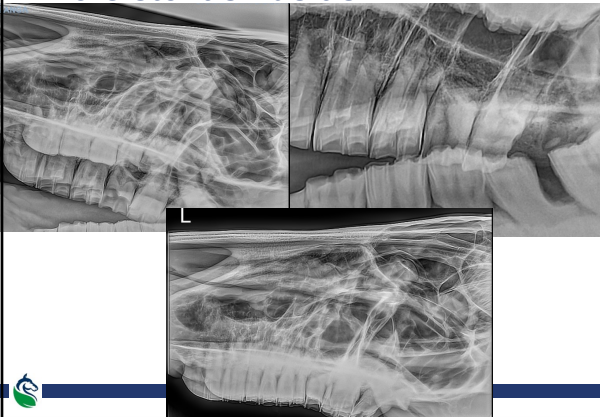
41

Persistent sinusitis



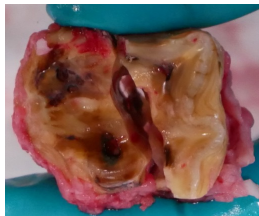
42

Persistent sinusitis



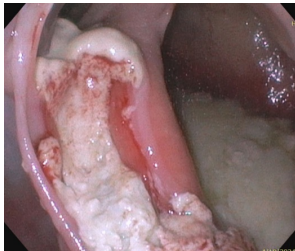
43

Persistent sinusitis



44

Persistent sinusitis



45

Questions?

My contact info:
Amelie McAndrews
908-907-6843 (mobile)
732-946-0767 (office)
McAndrews@GardenStateEquine.com