



# ACE THOSE SPAYS!

Tips and tricks from HQHVSN to help you every day

Laura Helmueller, DVM

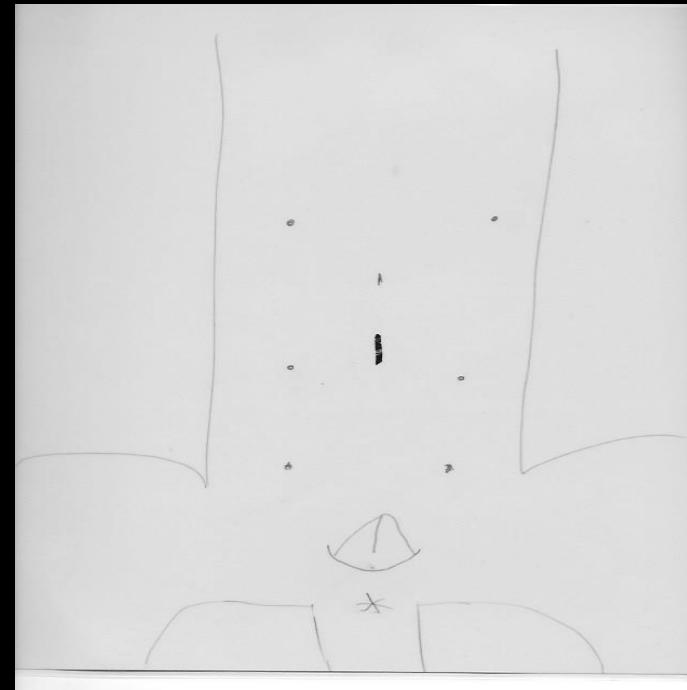



# HOW CAN A SPAY GET FASTER?

- Incision placement
- Spay hook
- Exteriorizing the ovaries
- Miller's knot as a single ligature
- Fast in and out

# INCISION PLACEMENT

- Mature dog – just below umbilicus
- Immature dog – the cranial 1/3 between the umbilicus and pubis
- Cats – just above the last set of nipples (cranial edge of the bladder)



# HOOKING

Know your anatomy

Spay hook is a 2-3 finger instrument

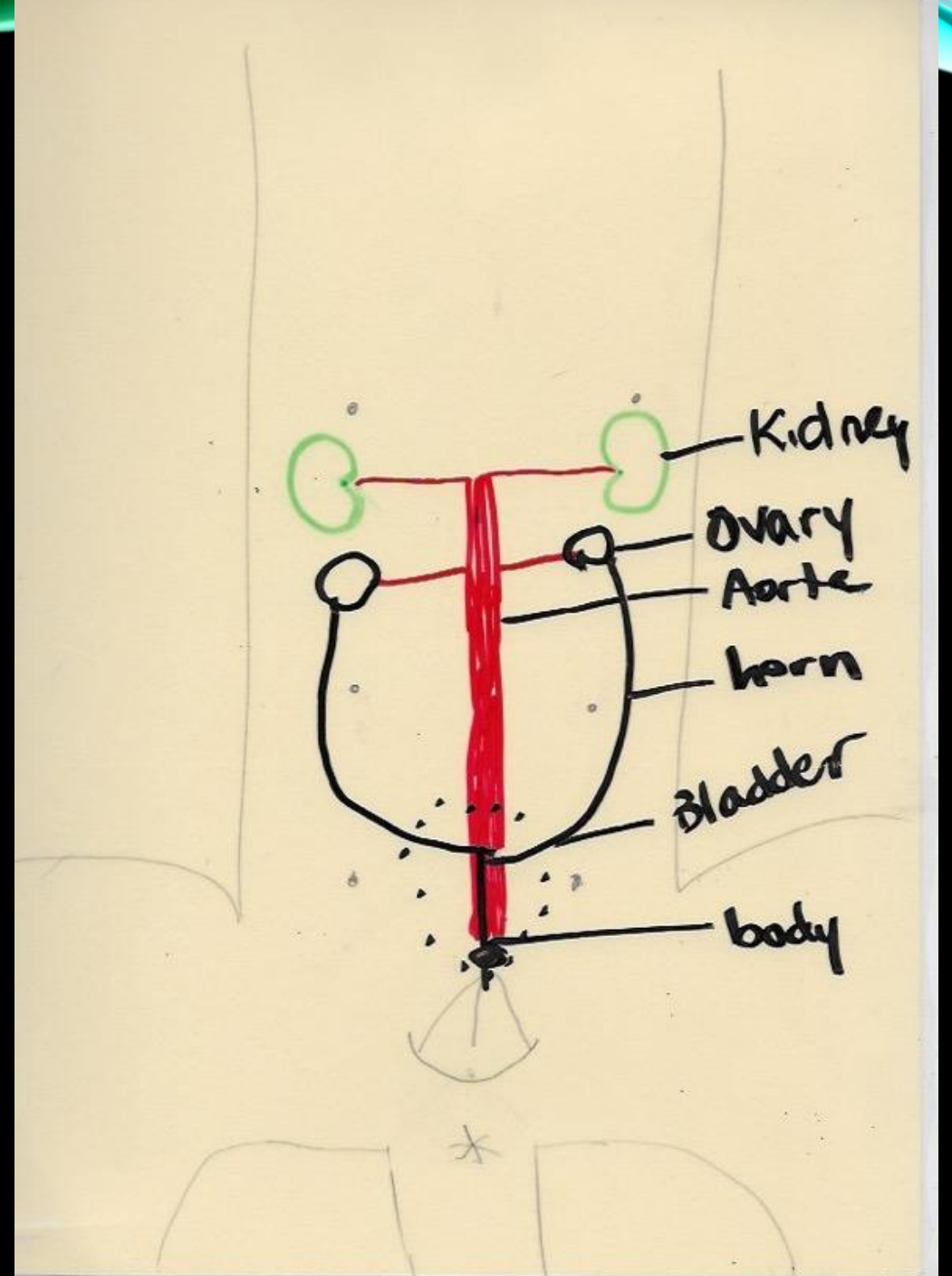
Hooking ureters?

retroperitoneal

only visible at the bladder

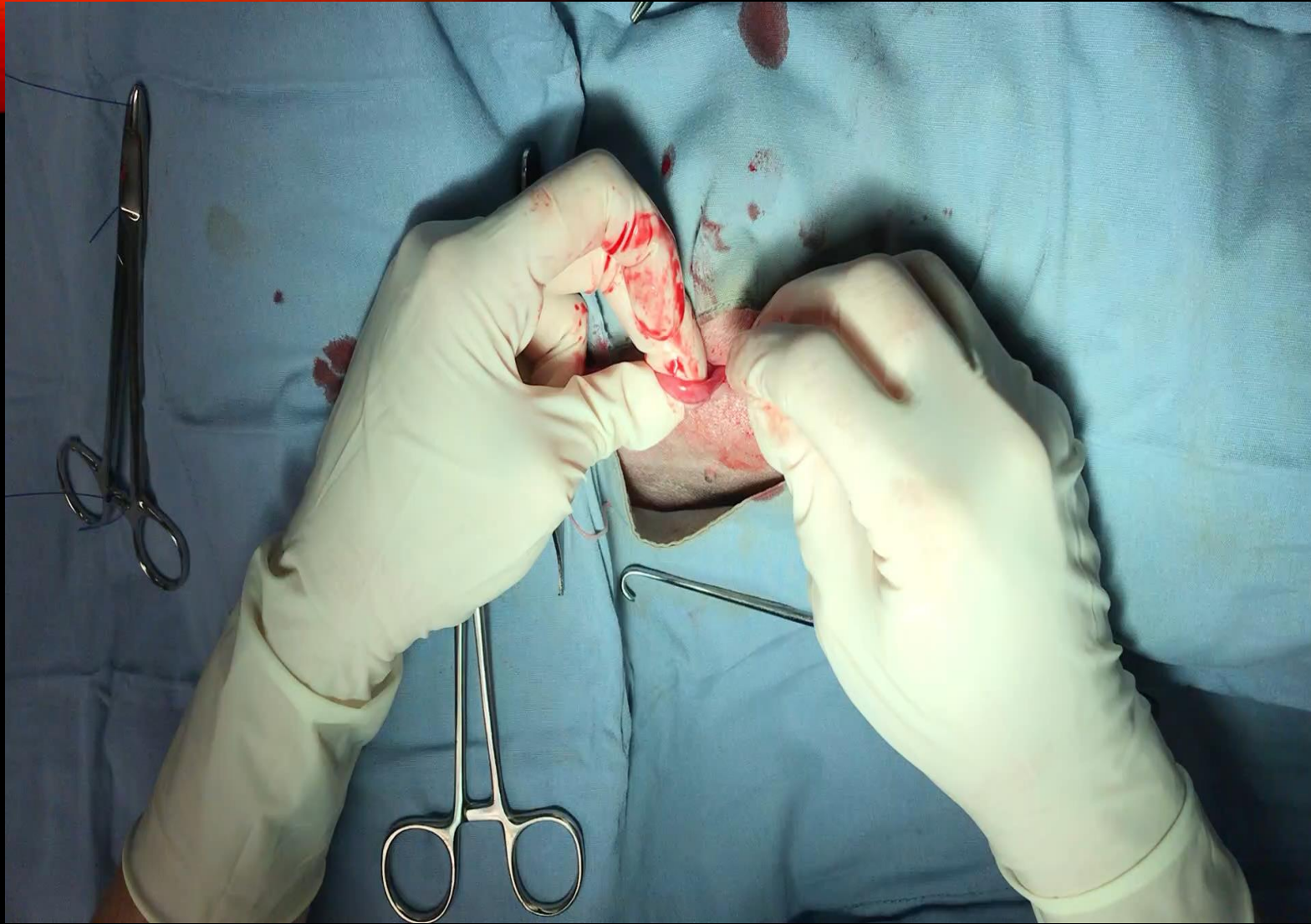
retroperitoneal

did I mention retroperitoneal?



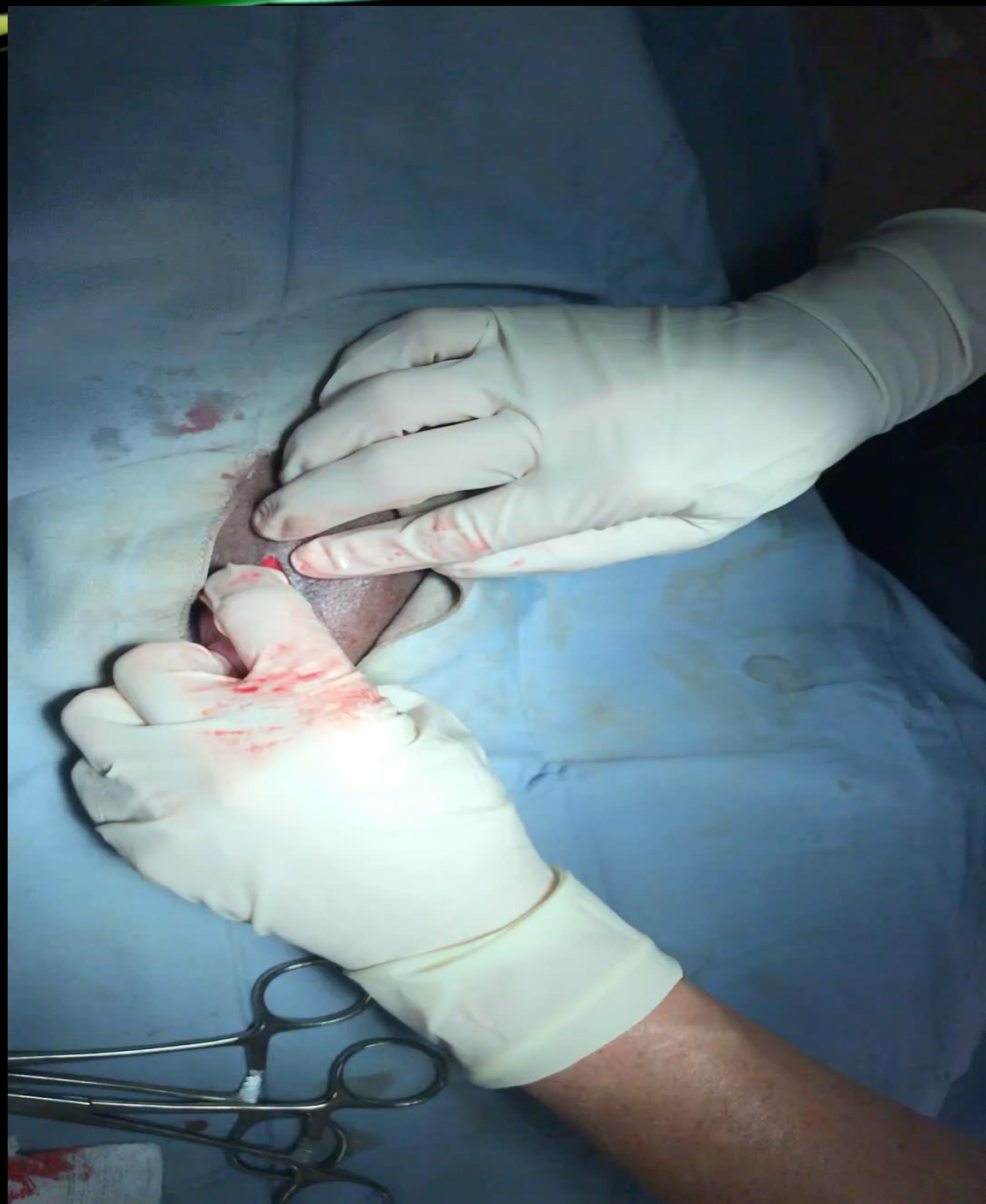# OH THAT OVARY

- Naked part of the uterus to the ceiling
- Direct the proper/suspensory ligament cranially
- Pull cranially and laterally – NOT caudally
  - Use your hand to push the body wall dorsally
  - Then grab under the ovary
- Cut or break the suspensory enough to release the ovary and then STOP PULLING
- Fenestrate BL – including artery of BL
- Place clamp up against the ovary so that there is plenty of room to tie the knot
- Turn the hemostat to expose more of the pedicle – place miller's knot



GETTING THAT  
OVARY OUT  
SMALL DOG

LARGE DOG

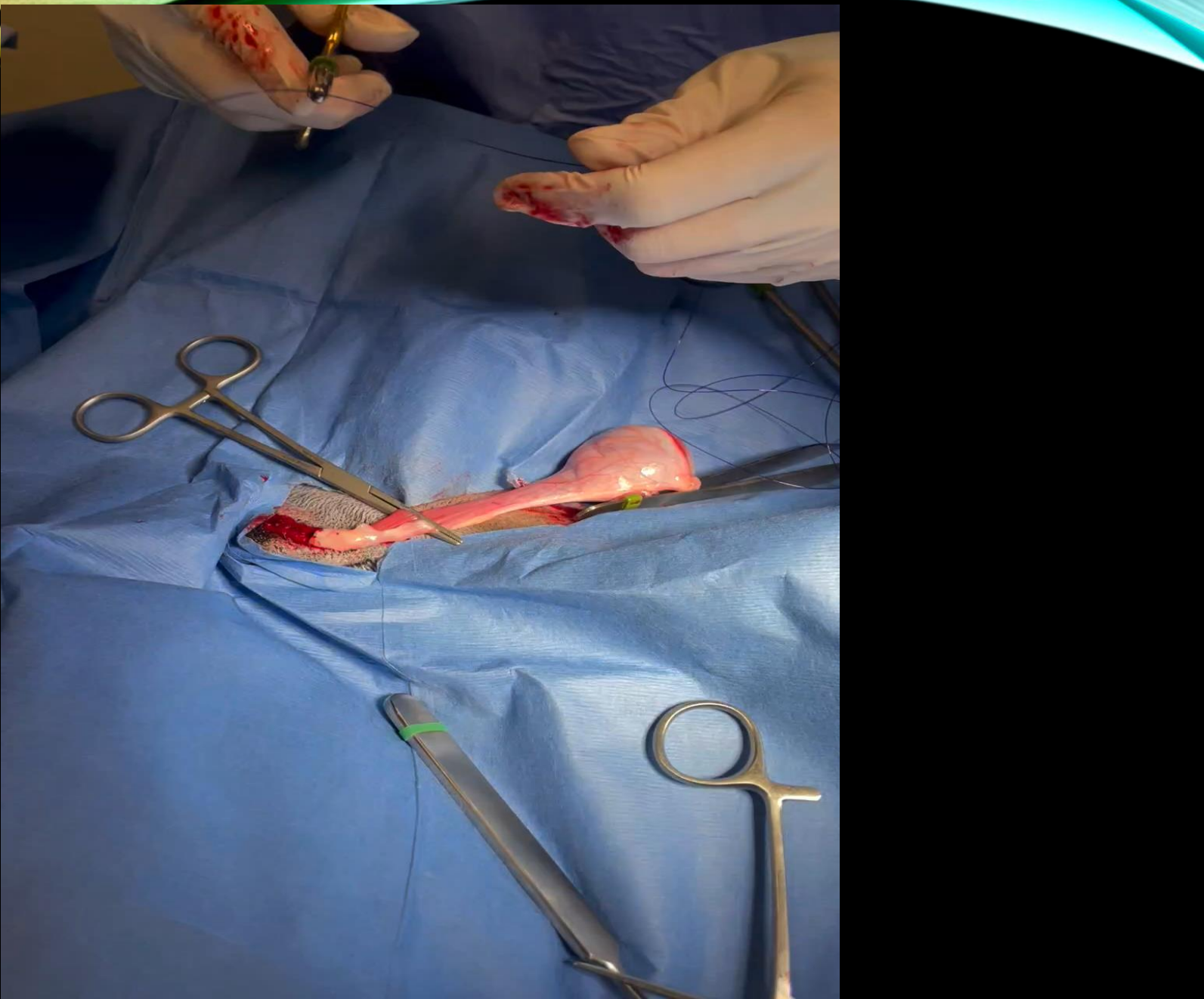


# OH THAT OVARY

- Naked part of the uterus to the ceiling
- Direct the proper/suspensory ligament cranially
- Pull cranially and laterally – NOT caudally
  - Use your hand to push the body wall dorsally
  - Then grab under the ovary
- Cut or break the suspensory enough to release the ovary and then STOP PULLING
- Place clamp up against the ovary so that there is plenty of room to tie the knot
- Miller's knot – turn the hemostat to expose more of the pedicle



# MILLERS

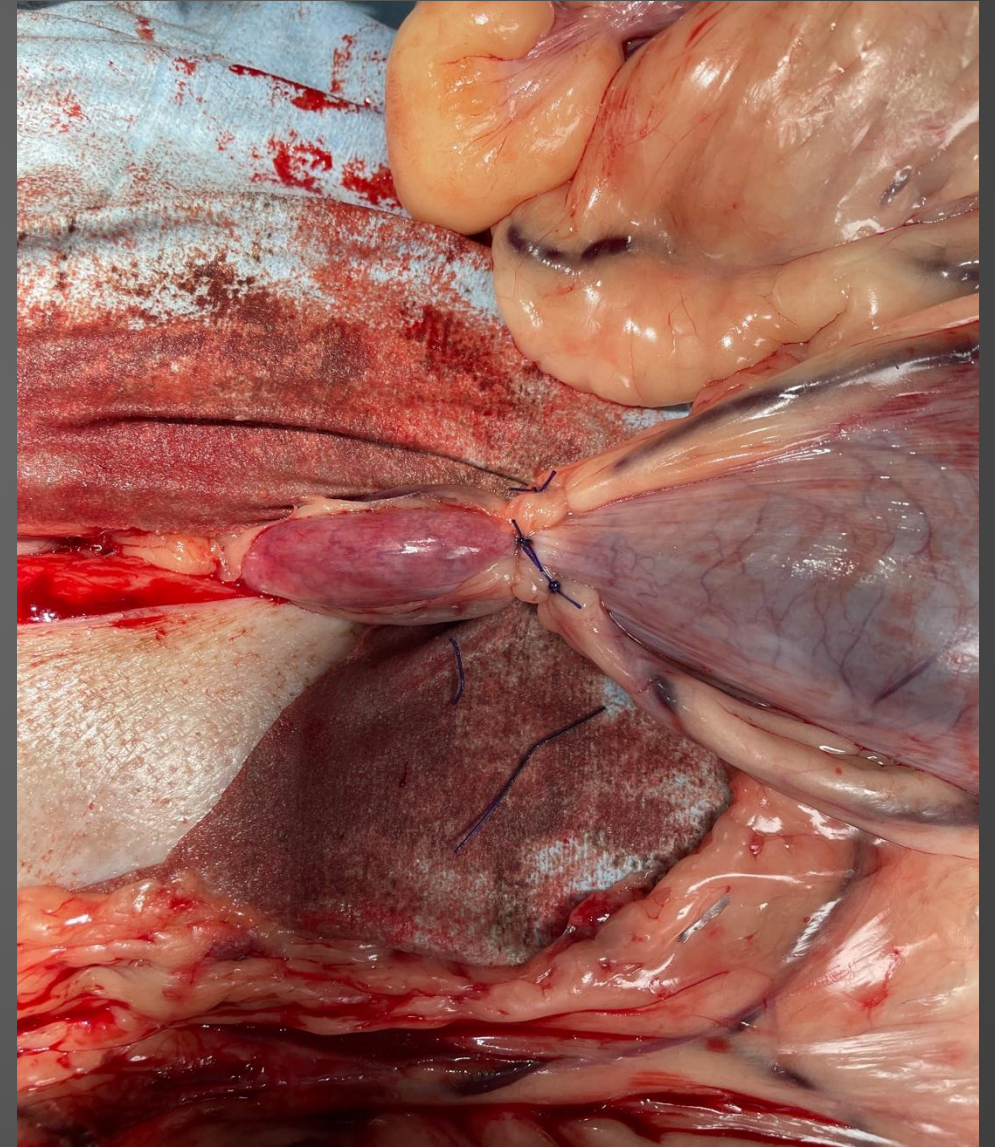

# DROPPED PEDICLE

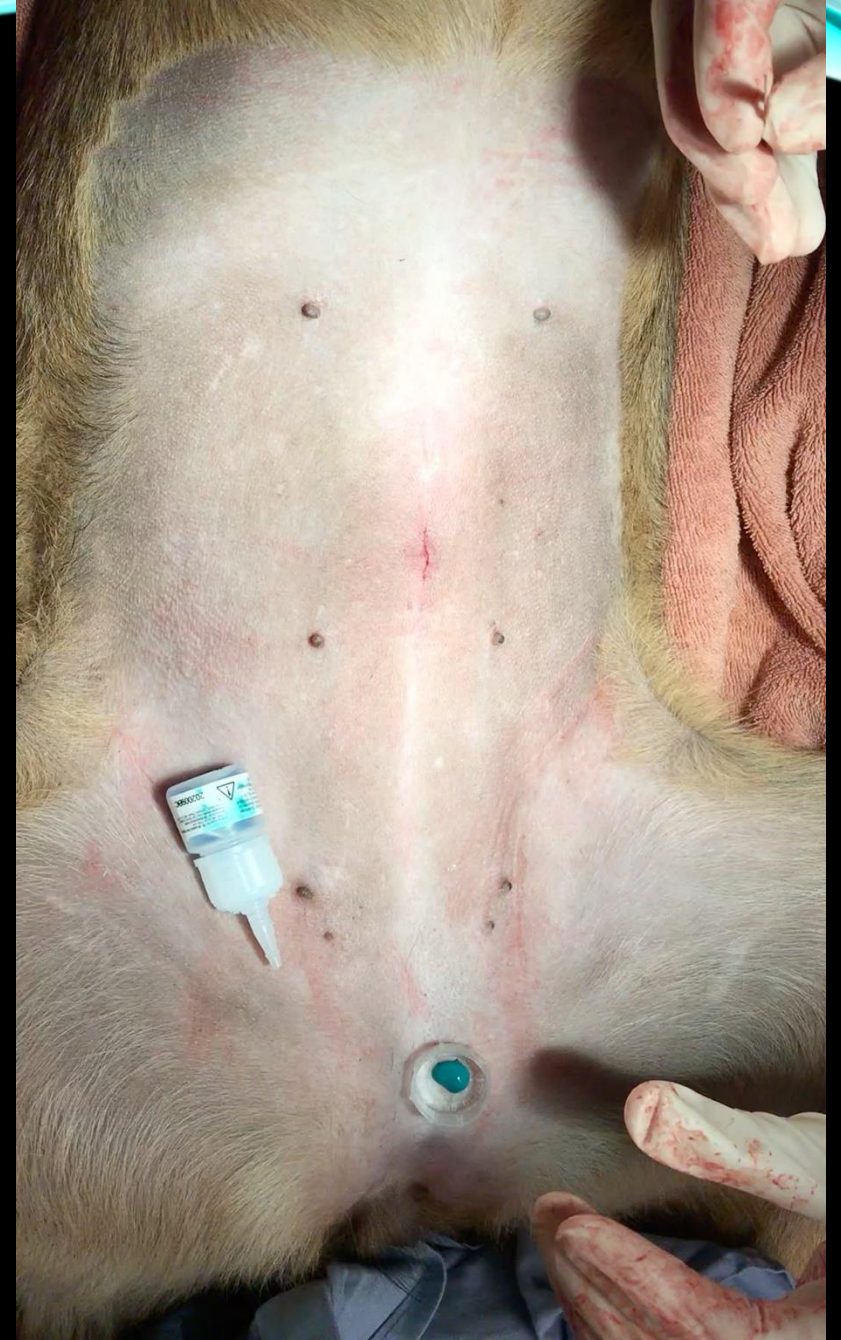- If you have a clamp slip or a pedicle tears –
  - STOP
  - Gather what you need
  - Extend your incision cranially
  - Very carefully use your broad ligament to bring the artery to the surface.
  - Clamp it and BREATHE.....
  - Tie your suture on the shaft of the clamp and slide it over the pedicle carefully.

# UTERINE BODY

- Broad ligament – to tear or tie off?
- No need to clamp the body
- Where should I tie off the body?
  - No need to get down to the cervix
  - OVE vs OHE
- Need extra insurance?
  - stick tights on the uterine arteries



- Body wall
  - Cruciates or continuous
- Skin – intradermal
- Glue to seal
- Tattoo – everyone likes a little ink!
- (Please tattoo, pretty please tattoo)



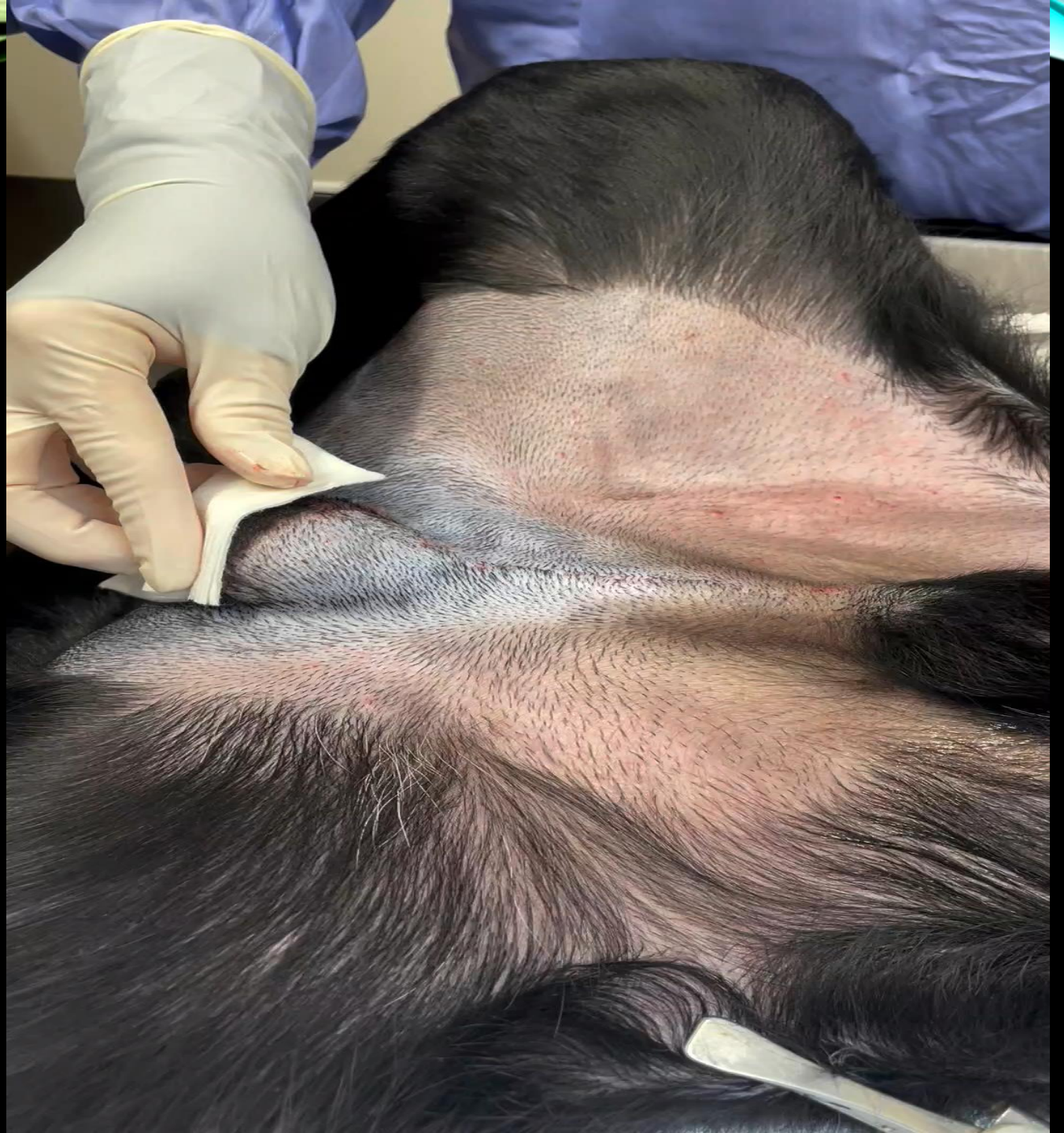# CRYPTORCHIDS

Approach landmarks

between the pubis and the  
2<sup>nd</sup> to last nipple

Stay away from RoE!

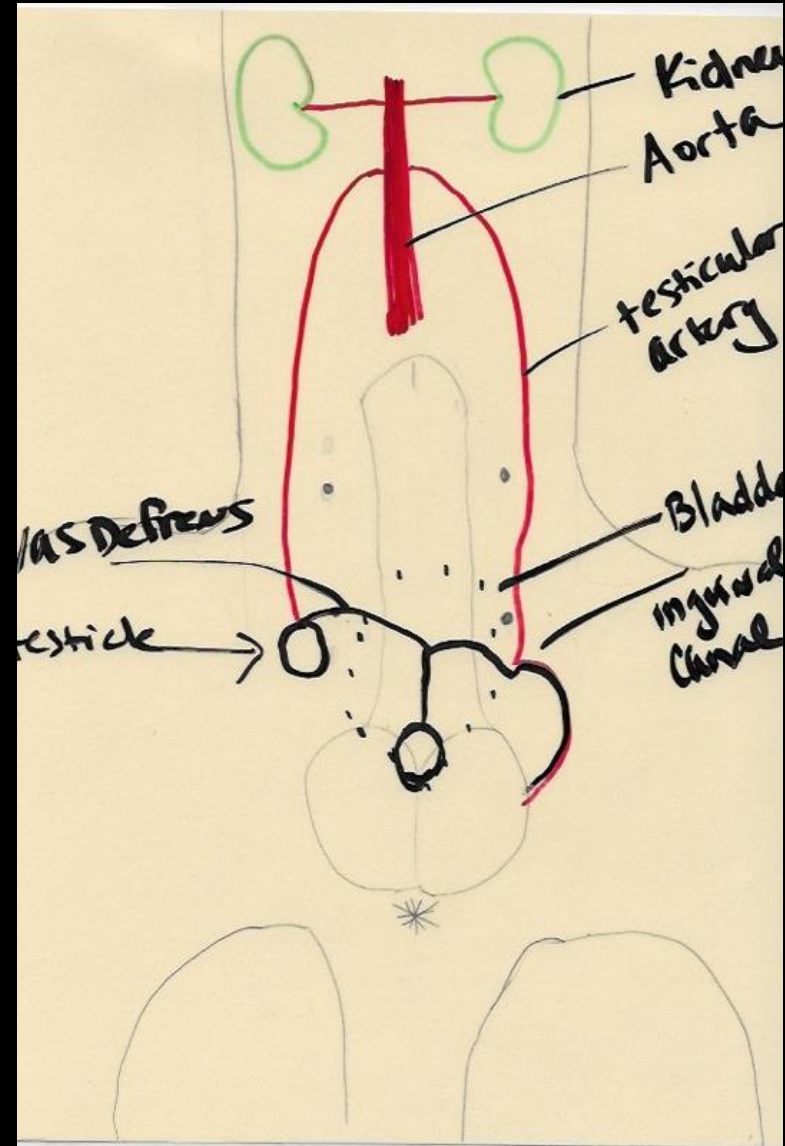
Easier to stand on the same side as the  
missing testicle



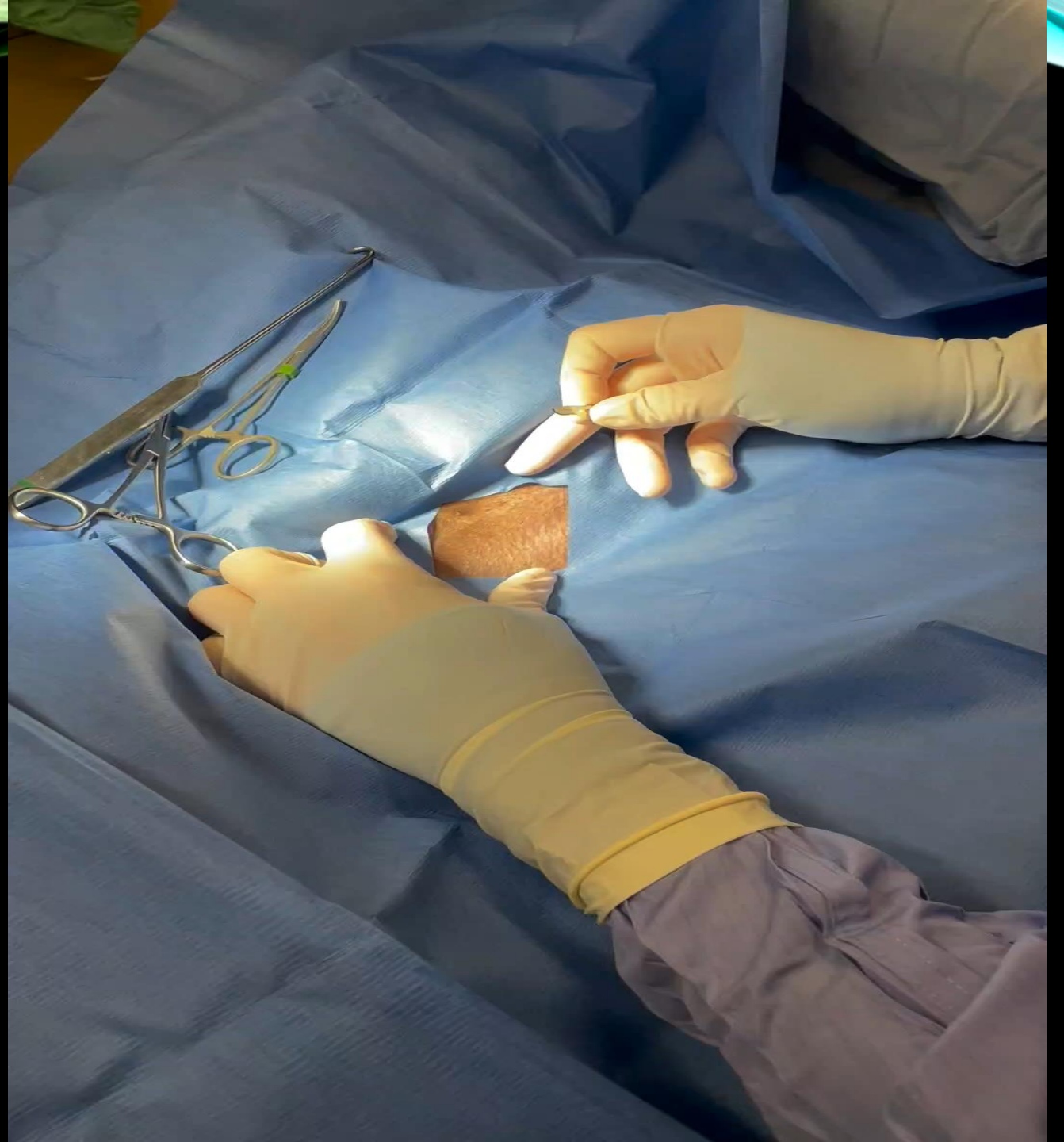
# REVIEW ANATOMY

Cats and dogs

Incidence of cryptorchids



# RIGHT CRYPTORCHID

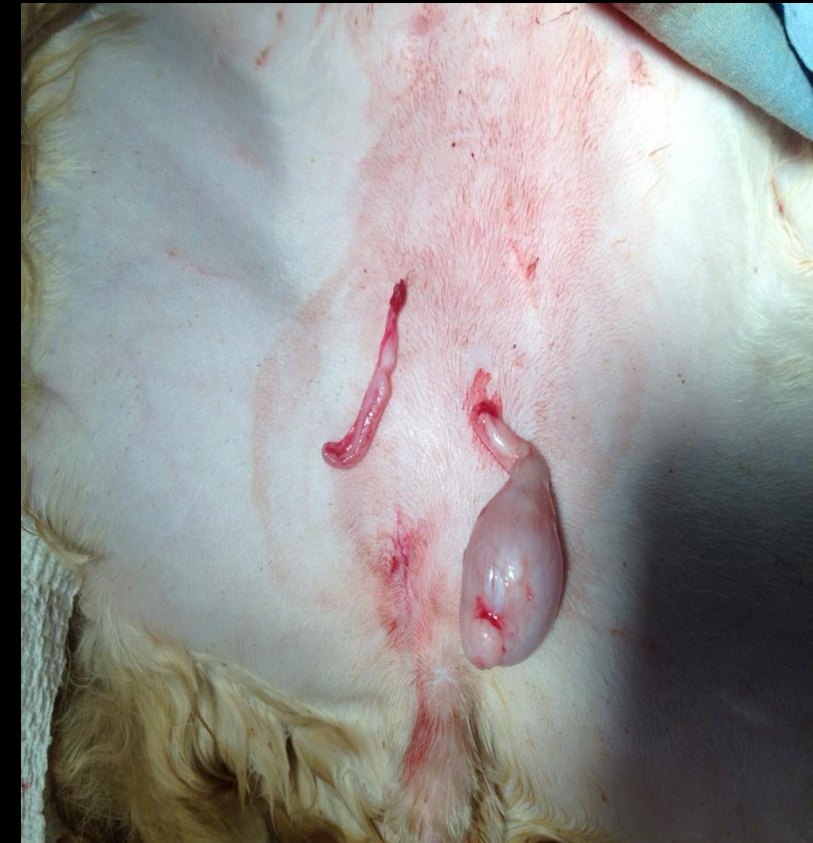

# WORRIED ABOUT A BLEED?

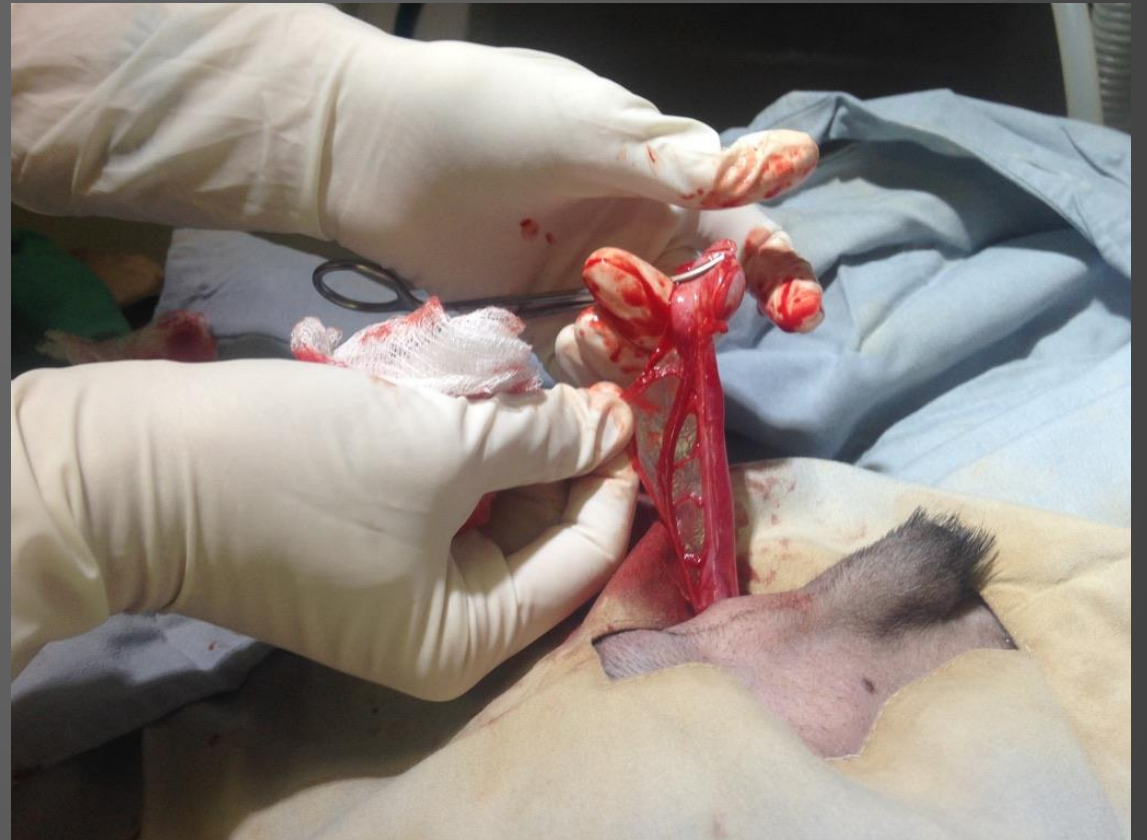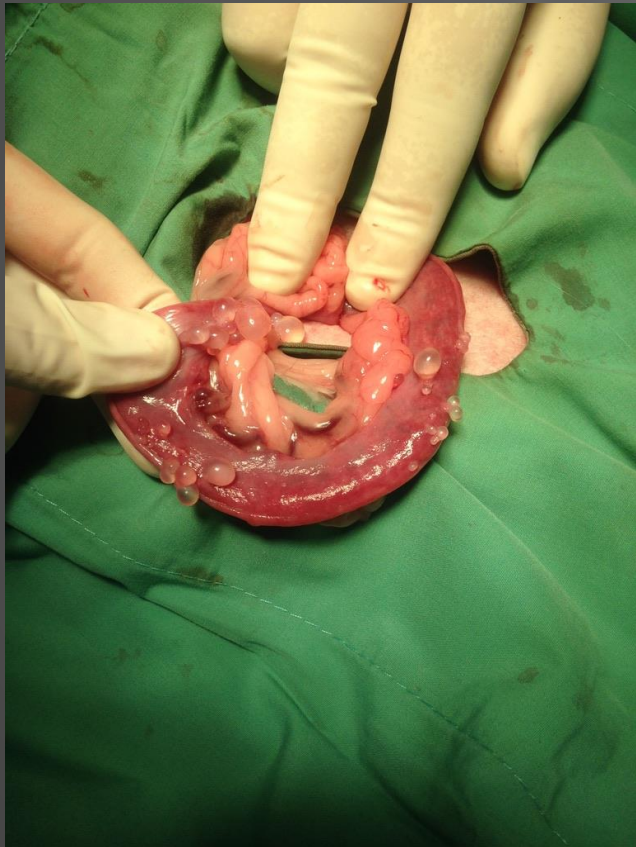- If you are at the end of surgery and feel like there is too much blood:
  - Extend your incision
  - Use a gauze on a hemostat to swab a gutter, then change gauze and do the other. If you have a clot on there – then there's a leak
  - Biologic retractors
    - Duodenum/pancreas and descending large colon
- If you are post op and are concerned – take a temp and HR q30 min. The trend should be temp goes down and hr goes up the first 30, then the temp should go up and HR down on subsequent readings.
- If you are not sure – take a HR then walk the patient around the room and take another HR. If >200 – you got a leak.

# SPECIAL CASES

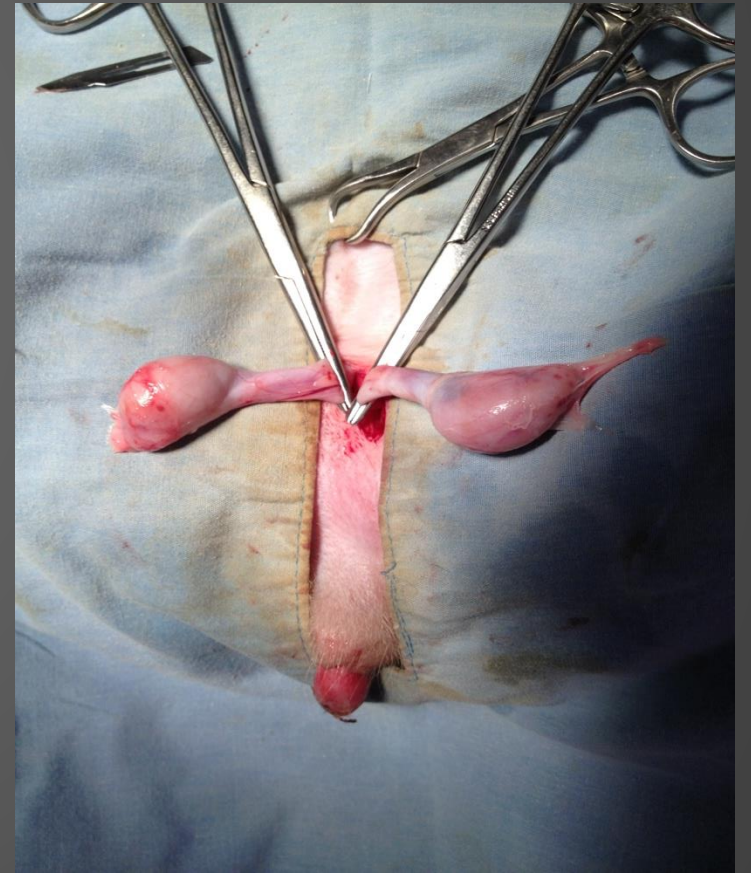
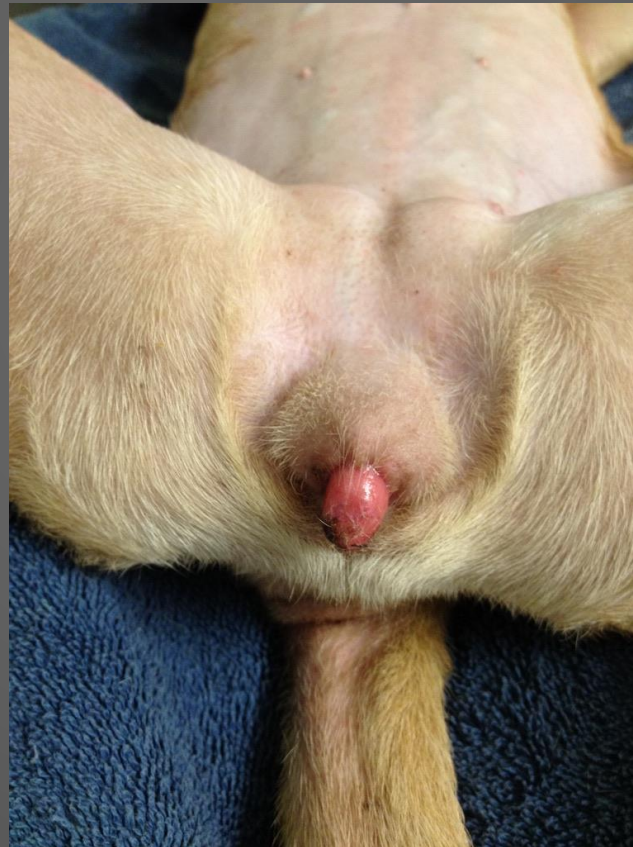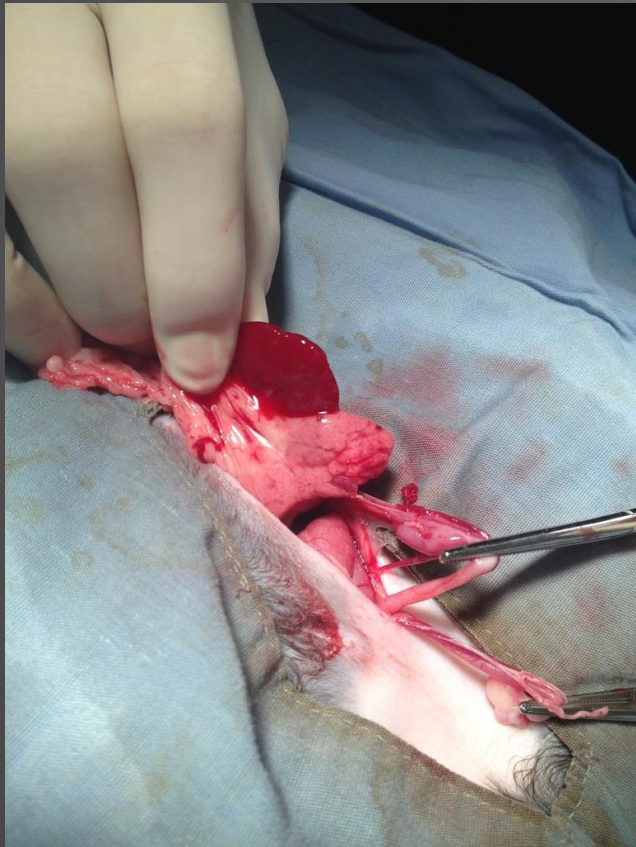
- Already been spayed? Gonadal remnant?
  - LH tests – good for males too!
  - Ovarian Remnant
    - Consider UTI or exogenous estrogens vs retained ovarian tissue
- Developmental abnormalities – the gonads are always there!



# A FEW OF MY FAVORITE THINGS



A FEW MORE....



# QUESTIONS??



A C E o f S P A Y S

- Laura Helmueller, DVM
- 210-364-3214
- [www.aceofspaysatx.com](http://www.aceofspaysatx.com)
- I offer an 8 hr CE class in surgery techniques